Доклади на Българската академия на науките
Comptes rendus de l'Académie bulgare des Sciences
*Tome 79, No 11, 2026*

*MEDICINE*
*Oral medicine*

# EFFECT OF SOCKET SEALING ABUTMENTS ON PERI-IMPLANT SOFT TISSUE HEIGHT AND THICKNESS IN IMMEDIATE IMPLANT PLACEMENT: A RANDOMIZED CLINICAL TRIAL

**Abdulmajid Mohamad Mohamad, Ahmed Tawfig Gamal**✉

*Received on June 15, 2026*
*Presented by D. Damianov, Member of BAS, on September 29, 2026*

**Abstract**

Following immediate implant placement, maintaining the dimensions of the peri-implant soft tissues is an essential part of aesthetic and functional success. Conventional healing abutments are not always the best solution to support soft tissue stability during early healing. As a result, socket sealing abutments are suggested as an alternative; Still, only few clinical cases have been documented. The current study aimed to investigate how socket sealing abutments impacted peri-implant soft tissue margin and thickness in immediate implant placement rather than conventional healing abutments. This randomized clinical trial was conducted on thirty adult patients who needed immediate posterior implant placement. They were randomly divided into two groups: test group got socket sealing abutments ($n = 15$) while control group got conventional healing abutments ($n = 15$). Peri-implant soft tissue height and thickness clinically were recorded at baseline, after implant placement, and at eight-week follow-up. For statistical analysis, Mann–Whitney U and Wilcoxon tests were used ($\rho < 0.05$). There was no noticeable difference in peri-implant soft tissue height between groups at eight weeks ($\rho = 0.620$). But the socket sealing abutment group preserved better the mid-buccal soft tissue ($\rho < 0.001$) and had higher Pink Esthetic Score ($9.27 \pm 0.88$ vs. $7.20 \pm 1.21$, $\rho < 0.001$) than conventional healing abutments. Bottom line, socket sealing abutments can be

This study was funded and supported by the Research Center of Riyadh Elm University, Riyadh, Saudi Arabia.
https://doi.org/10.7546/CRABS.2026.11.16

a good strategy to maintain peri-implant soft tissue dimensions after immediate implant placement, mostly with mid-buccal tissue stability and esthetic results better than conventional healing abutments.

**Key words:** dental implants, immediate implant, peri-implant soft tissue, socket sealing abutment, healing abutment

**Introduction.** Dental implantology is considered fundamental to modern restorative dentistry, capable of providing very dependable and permanent solutions to people with missing teeth. One of the methods that can be employed for immediate implantation, i.e. implant placement right after tooth extraction, has become famous as it shortens the total time of treatment, lessens the number of operations needed, helps preserve alveolar ridge shape, and even increases patient satisfaction [1, 2].

When a tooth is removed, the bone that supports it changes its shape. Within the first 12 months, 50% of the bone resorption is horizontal due to which the vertical loss is about 1–2 mm, mostly on the buccal side [2,3]. Such changes reduce the space for soft tissues and make the net less stable which in turn complicates the process of getting a long-lasting result [4]. Therefore, it necessitates to keep the peri-implant soft tissue dimensions unchanged.

Peri-implant soft tissue height is the length of mucosal tissue extending between the implant platform and the gingival margin whereas peri-implant soft tissue thickness is the width of the mucosal tissue protruding from the surface of the implant. Studies indicate that implant sites with less than 2 mm of mucosal tissue thickness are more susceptible to midfacial recession and peri-implant bone loss. However, a thicker tissue layer results in better aesthetic and functional outcomes [5, 6].

Socket sealing abutments (SSAs) have proved to be an extremely effective method – these modified therapeutic abutments, which are custom-made in the dental practice using liquid composite, are used to replicate the natural socket anatomy and emergence profile. Apart from sealing the grafted socket, SSAs also stabilize the gingiva and create an environment that is biologically favourable for healing, which conventional healing abutments (CHAs) do not offer immediately [7, 8]. According to Chokaree et al. [9] SSAs are more protective of the buccal tissues and give better aesthetic outcomes compared with standard abutments.

This study was conducted to examine the effect of socket sealing abutments on peri-implant soft tissue height and thickness in immediate implant placement in comparison with conventional healing abutments.

**Materials and methods.** ***Study design.*** We conducted this randomized controlled clinical trial with a parallel-arm setup and a 1:1 allocation ratio. The work was conducted at the Department of Periodontology, University Hospital of Riyadh Elm University, after obtaining Institutional Review Board approval (FPGRP/2025/915/1297/1173).

***Participants.*** We recruited thirty participants in total (15 each group), all of whom attended the entire 2-month follow-up period. The main inclusion criteria were healthy adults aged 18–65 years (American Society of Anesthesiologists [ASA] physical status classification I or II) who were single-tooth implant candidates in posterior areas (premolars or molars). They were required to have keratinized gingiva of at least 2 mm in width, intact buccal bone walls, and a Full-Mouth Plaque Score 25%. Smoking, systemic diseases that would affect healing, extensive grafting procedures, untreated periodontitis, local infections, pregnancy, or breastfeeding were among the exclusion criteria.

***Interventions.*** A minimally traumatic extraction was performed, and the alveolar socket was thoroughly cleaned before proceeding with the preparation for an osteotomy along the palatal/lingual wall. Immediate implants (Straumann Basel Switzerland; 3.3 mm for premolars, 4.1 mm for molars) were placed on the same day with primary stability ascertainment by a minimum insertion torque of 25 N/cm. Freeze-Dried Bone Allograft (Medical Lights, Riyadh, Saudi Arabia) was used for socket filling in all cases.

***Group A (SSA).*** Chairside customized socket sealing abutments were fabricated by initially securing prefabricated healing abutments. Flowable composite (Meta Biomed, Cheongiu-si, South Korea) was incrementally applied, shaped, and light-cured extra-orally to replicate the emergence profile of the extracted tooth and conform precisely to the socket anatomy. The customized abutment was then finished, polished, and immediately torqued onto the implant to support the soft tissue architecture as shown in Fig. 1.

***Group B (CHA).*** Immediately after implant insertion, prefabricated cylindrical healing abutments were placed together with the collagen plug for socket sealing. Primary closure was done by 4–0 monofilament sutures with removal after 2 weeks. The first and second follow-up visits were scheduled for 2 weeks and 8 weeks, respectively.

***Outcomes.*** The main outcome was peri-implant soft tissue height that was taken at the mid-buccal point from the free gingival margin to the most coronal exposed implant surface with a periodontal probe of type UNC-15. Secondary outcomes were soft tissue parameters (buccal, lingual mesial, distal, and gingival thickness) and Pink Esthetic Score (PES) assessment at 8 weeks [10].

***Statistical analysis.*** Data distribution was assessed using the Shapiro–Wilk test. Since the data failed to meet the assumption of normality, non-parametric statistical methods were chosen. Comparisons between groups employed the Mann–Whitney U test, while within-group comparisons used the Wilcoxon signed-rank test. Homogeneity of variances was confirmed prior to analysis using Levene's test. Statistical significance was set at $\rho < 0.05$. Analyses were performed using SPSS version 27.

**Results.** ***Reliability and baseline characteristics.*** Inter- and intra-examiner reliability were assessed, and results showed a remarkably elevated level

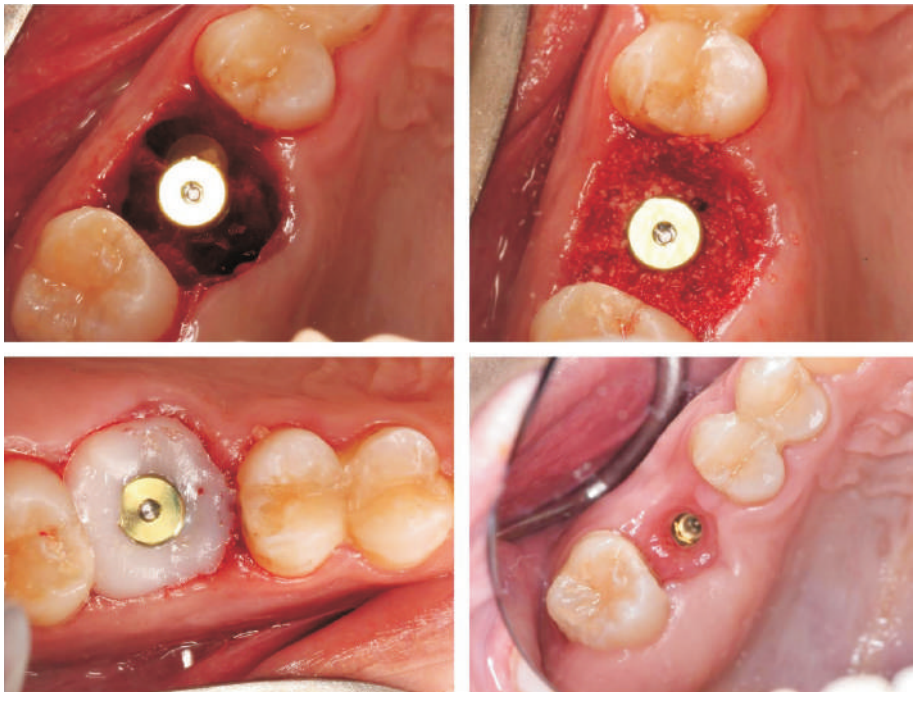

Fig. 1. Placement of socket sealing abutment

of agreement (Intraclass Correlation Coefficient [ICC] range: 0.914–1.000 and 0.984–1.000, respectively). Figure 2 depicts the demographics and clinical data distributions within each group. About gender, males made up 53.3% of the CHA group and 26.7% of the SSA group. As for gingival phenotype, both groups had the same percentage distribution (73.3% thin, 26.7% thick). The average age of the two groups was close (CHA: 43.87 ± 9.51 years; SSA: 41.47 ± 12.81 years).

***Primary outcomes.*** At eight weeks, the peri-implant soft tissue height did not differ between the two groups ($\rho = 0.620$) (Fig. 3). Analysis within groups indicated that the PISTH values remained unchanged in the two groups during the entire study period.

***Secondary outcomes.*** Changes of Soft Tissue Dimensions: At the eight-week follow-up, the SSA group showed better preservation of mid-buccal soft tissue than the CHA group ($4.93 \pm 1.10$ mm vs. $3.20 \pm 0.56$ mm, $\rho < 0.001$) (Fig. 2). The MB in the CHA group initially went up from $5.00 \pm 0.53$ mm at the baseline to $5.80 \pm 1.08$ mm right after implant placement, but in 8 weeks, it dropped to $3.20 \pm 0.56$ mm (AI-BL $\rho = 0.005$; Week 8-AI $\rho = 0.001$). Meanwhile, the SSA group exhibited an uptick of MB from $4.60 \pm 0.99$ mm baseline to $5.60 \pm 1.24$ mm after placement with a slight, statistically non-significant, reduction at 8 weeks ($4.93 \pm 1.10$ mm, $\rho = 0.059$).

Lingual/palatal changes were quite pronounced in the SSA group from base-

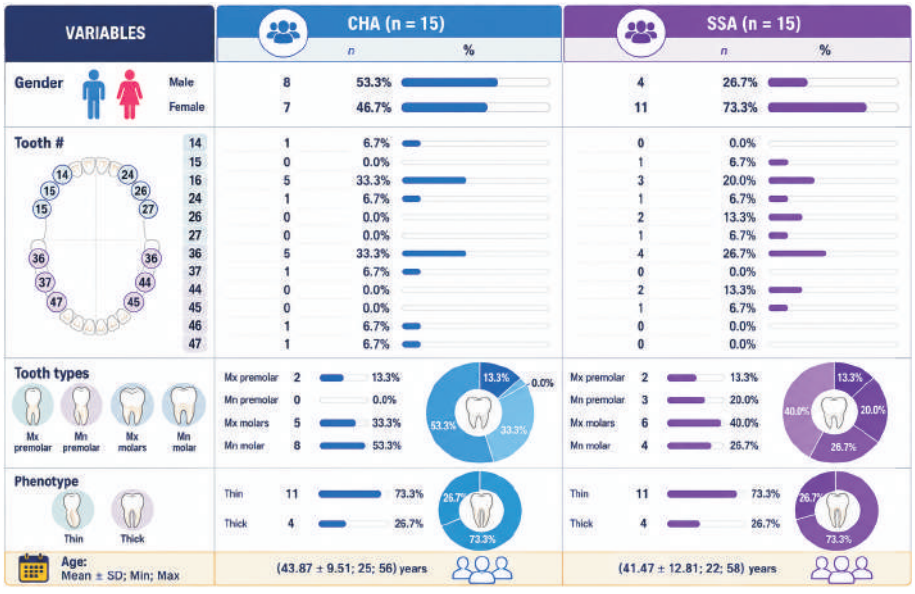


CHA – Conventional Healing Abutment; SSA – Socket Sealing Abutment

Fig. 2. Distribution of the study characteristics between the groups

| STAGES | VARIABLES | CHA | | | SSA | | | MW-U | p |
|---|---|---|---|---|---|---|---|---|---|
| | | Mean | SD | MR | Mean | SD | MR | | |
| Baseline (BL) | MB | 5.00 | 0.53 | 18.1 | 4.60 | 0.99 | 12.9 | 73.500 | 0.074 |
| | ML-P | 4.87 | 0.64 | 17.3 | 4.60 | 0.99 | 13.7 | 85.500 | 0.224 |
| | MM | 5.27 | 0.88 | 18.2 | 4.60 | 1.06 | 12.8 | 72.000 | 0.078 |
| | MD | 5.27 | 0.88 | 18.2 | 4.60 | 1.06 | 12.8 | 72.000 | 0.078 |
| After Implant (AI) | MB | 5.80 | 1.08 | 16.4 | 5.60 | 1.24 | 14.57 | 98.500 | 0.545 |
| | ML-P | 4.20 | 0.94 | 18.5 | 3.60 | 0.91 | 12.5 | 67.500 | 0.046 |
| | MM | 5.00 | 0.93 | 17.3 | 4.53 | 1.06 | 13.7 | 85.500 | 0.242 |
| | MD | 5.40 | 1.12 | 18.1 | 4.67 | 1.11 | 12.87 | 73.000 | 0.088 |
| 8-week Follow Up (8w) | MB | 3.20 | 0.56 | 9.27 | 4.93 | 1.10 | 21.73 | 19.000 | <0.001 |
| | ML | 3.33 | 0.62 | 14.8 | 3.60 | 0.91 | 16.2 | 102.000 | 0.622 |
| | MM | 5.00 | 0.93 | 17.3 | 4.53 | 1.06 | 13.7 | 85.500 | 0.242 |
| | MD | 5.33 | 1.05 | 18 | 4.67 | 1.11 | 13 | 75.000 | 0.103 |
| Baseline (BL) | AG | 4.20 | 1.21 | 15.6 | 4.20 | 0.94 | 15.4 | 111.000 | 0.948 |
| 8-week Follow Up (8w) | AG | 4.13 | 1.13 | 15.4 | 4.20 | 0.94 | 15.6 | 111.000 | 0.948 |
| After Implant (AI) | PISTH | 4.07 | 0.88 | 14.6 | 4.27 | 0.70 | 16.4 | 99.000 | 0.549 |
| 8-week Follow Up (8w) | PISTH | 4.13 | 0.74 | 14.8 | 4.27 | 0.70 | 16.23 | 101.500 | 0.620 |

MB – Mid buccal; ML-P – Mid lingual-palatal; MM – Mid-mesial; MD – Mid-distal; AG – Attached gingiva; PISHT – Peri-implant soft tissue height; MW-U – Mann–Whitney U analysis

Fig. 3. Comparison of soft tissue changes between CHA and SSA groups at various stages

line to both postoperative stages ($4.60 \pm 0.99$ mm to $3.60 \pm 0.91$ mm, $\rho = 0.001$), and there were no differences between the AI and Week 8 stages ($\rho = 1.000$). Interproximal dimensions (MM and MD) were found to be stable throughout the stages in both groups ($\rho > 0.05$).

***Esthetic results.*** The SSA group scored higher on the Pink Esthetic Scores ($9.27 \pm 0.88$) than the CHA group ($7.20 \pm 1.21$) ($\rho < 0.001$).

Further looking into individual PES items showed (Fig. 4a) that the SSA group had much better soft tissue colour ($1.80 \pm 0.41$ vs. $1.33 \pm 0.49$, $\rho = 0.009$), distal papilla ($2.00 \pm 0.00$ vs. $1.53 \pm 0.52$, $\rho = 0.004$), and mesial papilla ($2.00 \pm 0.00$ vs. $1.53 \pm 0.52$, $\rho = 0.004$). All implants (100%) in the SSA group achieved excellent PES (scores 8–10) as compared (Fig. 4b).

| Components | CHA (n = 15) | | SSA (n = 15) | | t | df | p |
|---|---|---|---|---|---|---|---|
| | Mean | SD | Mean | SD | | | |
| Soft tissue Level | 1.40 | 0.51 | 1.73 | 0.46 | -1.890 | 28 | 0.069 |
| Soft tissue Contour | 1.40 | 0.51 | 1.73 | 0.46 | -1.890 | 28 | 0.069 |
| Soft tissue Color | 1.33 | 0.49 | 1.80 | 0.41 | -2.824 | 28 | **0.009** |
| Distal papilla | 1.53 | 0.52 | 2.00 | 0.00 | -3.500 | 14 | **0.004** |
| Mesial papilla | 1.53 | 0.52 | 2.00 | 0.00 | -3.500 | 14 | **0.004** |

(a)

| Group | Excellent (8–10) | Clinically acceptable (5–7) | Poor (<5) |
|---|---|---|---|
| CHA (Control) | 6 (40%) | 9 (60%) | 0 (0%) |
| SSA (Test) | 15 (100%) | 0 (0%) | 0 (0%) |

(b)

Fig. 4. (a) Comparison of PES components between groups; (b) Distribution of PES interpretation categories

**Discussion.** This randomized clinical trial assessed early peri-implant soft tissue dimensional changes and esthetic results after immediate posterior implant placement with socket sealing abutments versus conventional healing abutments. Primary results showed that peri-implant soft tissue height was not significantly different between two groups after eight weeks, with contemporary SSA leading to significant mid-buccal soft tissue preservation and esthetic results.

The lack of notable change in vertical bone levels supports previous findings that with proper surgical technique, placing an implant immediately can preserve early crestal bone stability without considering healing abutment design [9, 11]. Cosyn et al. [12] found that during the first healing stage the design of the transmucosal component has less influence on bone stability versus the implant placement and surgical method.

However, vertical stability alone does not guarantee optimal esthetic results, as horizontal soft tissue contour critically determines patient-perceived esthetic success. The control group showed less maintenance of the horizontal mucosal margin, with statistically significant inward folding observed at multiple time points. This indicates that CHA contours permit peri-implant mucosa to collapse toward the implant surface during early healing, particularly in posterior sites where buccal bone is thinner and keratinized tissue is limited [13, 14].

The test group demonstrated excellent horizontal architecture preservation, maintaining high mucosal margin readings. This observation is biologically plausible because the anatomically contoured socket sealing abutment acts as a temporary transmucosal scaffold supporting the supra-crestal soft tissue complex during clot maturation and early tissue organization. Previous clinical investigations have reported that socket sealing concepts may limit dimensional changes in peri-implant tissues by protecting the extraction socket and supporting peri-implant mucosal contour during healing [7, 8].

The majority of SSA clinical trials have focused on anterior regions, but posterior areas are equally susceptible to dimensional compression forces. Zawawi et al. [15] and Assiri et al. [16] reported a high prevalence of thin gingival biotype in Saudi populations (approximately 48.8%), indicating susceptibility to soft tissue collapse during immediate implant healing. Both study arms showed similar thin/thick, soft tissue proportions at baseline (73.3% thin, 26.7% thick, $\rho = 1.000$), confirming that observed advantages were attributable to the device rather than patient selection.

The PES results suggest that customized composite abutments yield favourable early esthetic outcomes in immediate implant protocols. However, it is important to emphasize that variations and contradictions exist within the literature regarding the efficacy of different transmucosal designs. Furthermore, these short-term results do not guarantee long-term stability, and the preliminary esthetic advantages observed should not be viewed as permanently superior until confirmed by extended functional loading [10]. The superior esthetic outcome observed in the SSA group may be attributed primarily to the anatomically contoured design, which helps maintain the natural emergence profile immediately after implant-placement. Unlike conventional cylindrical healing abutments, SSAs seal the extraction socket coronally and support peri-implant soft tissues in a configuration closely mimicking the cervical morphology of the extracted tooth.

***Limitations.*** The eight-week follow-up period captures only early soft tissue maturation and does not reflect long-term stability. Extended follow-up would provide insight into whether observed esthetic advantages persist under functional loading. The sample size, while sufficient to detect significant PES differences, precluded subgroup analyses based on biotype or implant position.

**Conclusion.** Within the limitations of this randomized clinical trial, peri-implant soft tissue height showed no statistically significant difference between

SSA and CHA at eight-week follow-up ($\rho = 0.620$). However, socket sealing abutments demonstrated better early mid-buccal soft tissue preservation ($\rho < 0.001$) and favourable initial peri-implant soft tissue esthetic outcomes as measured by the Pink Esthetic Score ($\rho < 0.001$) compared with conventional healing abutments in immediate posterior implants. Extensive long-term data is still required to confirm ongoing esthetic stability.

Future research should track changes over extended timescales to evaluate long-term stability under functional loading and incorporate patient-reported outcome measures to enrich understanding of how soft tissue esthetics influence clinical success.

## REFERENCES


[1] Botticelli D., T. Berglundh, J. Lindhe (2004) Hard-tissue alterations following immediate implant placement in extraction sites, J. Clin. Periodontol., **31**(10), 820–828.

[2] Araújo M. G., F. Sukekava, J. L. Wennström et al. (2005) Ridge alterations following implant placement in fresh extraction sockets: an experimental study in the dog, J. Clin. Periodontol., **32**(6), 645–652.

[3] Araújo M. G., J. L. Wennström, J. Lindhe (2006) Modeling of the buccal and lingual bone walls of fresh extraction sites following implant installation, Clin. Oral Implants Res., **17**(6), 606–614.

[4] Araújo M. G., F. Sukekava, J. L. Wennström et al. (2006) Tissue modeling following implant placement in fresh extraction sockets, Clin. Oral Implants Res., **17**(6), 615–624.

[5] Thoma D. S., N. Naenni, E. Figuero et al. (2018) Effects of soft tissue augmentation procedures on peri-implant health or disease: A systematic review and meta-analysis, Clin. Oral Implants Res., **29**, 32–49, https://doi.org/10.1111/clr.13114.

[6] Suárez-López Del Amo F., G. H. Lin, A. Monje et al. (2016) Influence of soft tissue thickness on peri-implant marginal bone loss: A systematic review and meta-analysis, J. Periodontol., **87**(6), 690–699, https://doi.org/10.1902/jop.2016.150571.

[7] Lilet R., M. Desiron, G. Finelle et al. (2022) Immediate implant placement combining socket seal abutment and peri-implant socket filling: A prospective case series, Clin. Oral Implants Res., **33**(1), 33–44.

[8] Studenikin R., S. Niftaliev (2021) Fabrication and use of a customized provisional composite abutment in dental practice, Int. J. Dent., **2021**, 9929803.

[9] Chokaree P., P. Poovarodom, P. Chaijareenont et al. (2024) Effect of customized and prefabricated healing abutments on peri-implant soft tissue and bone in immediate implant sites: A randomized controlled trial, J. Clin. Med., **13**(3), 886.

[10] Fürhauser R., D. Florescu, T. Benesch et al. (2005) Evaluation of soft tissue around single-tooth implant crowns: the pink esthetic score, Clin. Oral Implants Res., **16**(6), 639–644.

[11] Sutariya P. V., S. P. Mehta., H. Upadhyay et al. (2022) The soft tissue esthetic outcome with and without immediate provisionalization in immediate implants: A systematic review and meta-analysis, J. Indian Prosthodont. Soc., **22**(1), 2–12, https://doi.org/10.4103/jips.jips_227_21.
[12] Cosyn J., N. Hooghe., H. De Bruyn (2012) A systematic review on the frequency of advanced recession following single immediate implant treatment, J. Clin. Periodont., **39**(6), 582–589, https://doi.org/10.1111/j.1600-051X.2012.01888.x.
[13] Tan W. L., T. L. T. Wong, M. C. M. Wong et al. (2012) A systematic review of post-extraction alveolar hard- and soft-tissue dimensional changes in humans, Clin. Oral Implants Res., **23**, 1–21.
[14] Avila-Ortiz G., L. Chambrone, F. Vignoletti (2019) Effect of alveolar ridge preservation interventions following tooth extraction: A systematic review and meta-analysis, J. Clin. Periodontol., **46**, 195–223.
[15] Zawawi K. H., S. M. Al-Harthi, M. S. Al-Zahrani (2012) Prevalence of gingival biotype and its relationship to dental malocclusion, Saudi Med. J., **33**(6), 671–675.
[16] Assiri M., S. Shafik, A. Tawfig (2019) Association between gingival tissue biotype and different facial phenotypes, Saudi Dent. J., **31**(4), 467–480.

*Department of Preventive Dentistry, College of Medicine and Dentistry,*
*Riyadh Elm University, Riyadh 12734, Saudi Arabia*
*e-mails*: abdulmajid.m.mohamad@student.ryadh.edu.sa,
ahmed.tawfig@riyadh.edu.sa