Доклади на Българската академия на науките
Comptes rendus de l'Académie bulgare des Sciences
Tome 79, No 11, 2026

MEDICINE
Oral medicine

AI-DEEP LEARNING-BASED MORPHOMETRIC ASSESSMENT OF PERI-IMPLANT TISSUES: A COMPARATIVE STUDY OF 2D AND 3D RADIOGRAPHIC MODALITIES

Zeeshan Qamar✉, Naser Taqi, Mustafa Amous, Khaled Hasan Alkhatib, Hussain Alenezi

Received on June 17, 2026
Presented by D. Damianov, Member of BAS, on September 29, 2026

Abstract

Dental implant therapy has expanded a lot, which means we now need more reliable imaging methods to early detect peri-implant diseases. Artificial intelligence (AI), mainly convolutional neural networks (CNNs), is a great way to help dental implant radiologists make a diagnosis. This paper aims to evaluate an AI system in comparison to different imaging methods, namely traditional 2D panoramic radiographs (OPG) and 3D cone beam computed tomography (CBCT), in detecting and classifying peri-implant conditions including peri-implantitis (PI), retrograde peri-implantitis (RPI), and prosthetically induced bone loss. In total, the authors analyzed 824 implants (428 healthy, 396 diseased) from OPG and CBCT images. The authors selected DenseNet121, a CNN model, and used transfer learning to train it to classify lesions. The diagnostic performance of the model was measured by accuracy sensitivity specificity, F1-score, and ROC curve area (AUC). The Hanley and McNeil methods were used for modality comparisons. The model exhibited moderate to strong diagnostic capabilities for both imaging techniques with the ROC AUC values between 0.630 and 0.755. CBCT gave a higher accuracy result in detecting maxillary retrograde peri-implantitis (AUC: 0.710 vs. 0.635; $\rho = 0.016$) whereas OPG was superior in identifying mandibular peri-implantitis (AUC: 0.755 vs. 0.630; $\rho < 0.001$). On examining prosthetically induced bone loss, both methods yielded similar outcomes. The results show that

https://doi.org/10.7546/CRABS.2026.11.17

the CNN models are reliable in diagnosing peri-implant lesions, but a person's diagnostic performance would depend on the lesion's type and its anatomical location. CBCT would be more suitable for complex apical lesions, whereas OPG is still good for assessing marginal bone changes.

Key words: artificial intelligence, deep learning, convolutional neural networks, peri-implantitis, cone-beam computed tomography, panoramic radiography

Introduction. The worldwide increase in dental implant procedures is driving a higher demand for effective diagnostic tools to handle complications like peri-implant diseases, which can dramatically influence the implant treatment outcomes over time [1]. Disease progression in PI is usually painless and without any symptoms; this makes the role of early and precise diagnosis extremely important for maintaining the stability of the bone-implant interface and for preventing implant loss [2]. Recently, developments in AI and deep learning technology have revolutionized the analysis of medical imaging. These computational models, consisting of multiple layers, can carry out highly intricate operations like image segmentation, classification, and feature extraction, achieving high level of accuracy [3]. Dental procedures supported by artificial intelligence have helped to reduce diagnostic errors, known as 'observer variability'; furthermore, in some cases, their level of effectiveness is on a par with that of human specialists or even exceeds it [4].

The CNNs among these AI methods have proven to be excellent at the task of interpreting radiographic images as they can learn the features of images in a hierarchical manner. Uses reported have included detecting dental caries, screening for oral cancer, and identifying dental implants [5]. For the same reason health professionals consider use of CNNs possible to detect and even categorize peri-implant lesions [6]. Using AI, the diagnostic process can be made more straightforward, less prone to subjective interpretation errors and can yield highly predictable outcomes of implant treatment [3]. Besides, these automated systems work as a great help to the clinicians in visualizing peri-implant bone defects and developing an effective treatment plan [7]. In fact, the nature of the diagnosis of bone changes from radiographs is very complex; So, there is an ever-increasing demand for intelligent systems that can make improvements in both diagnostic accuracy and efficiency [8].

AI is being used for research into implant identification as well as for implant survival prediction and implant design optimization [9]. With the use of panoramic radiographs and CBCT images, this research is centred on assessing different CNN models plus DenseNet121 to recognize PI, RPI, and prosthetically induced bone loss. The goal was to design a dependable, automated system that enables doctors to easily differentiate healthy peri-implant tissues from diseased ones with utmost sensitivity and specificity by utilizing transfer learning and pretrained models on a dataset from the peri-implant diseases domain.

Materials and methods. In this diagnostic accuracy study, we utilized a retrospective cross-sectional design. Before collecting data, we obtained ethical clearance from the Research and Innovation Centre at Riyadh Elm University, Riyadh Saudi Arabia. Since all the radiographic images were originally captured for routine clinical care, there was no need for additional radiation exposure. The patient identifiers were removed, and the dataset was made anonymous before any analysis was done.

Radiographic data was collected from the Dentoplus digital database at the Dental Hospital of Riyadh Elm University. The records of panoramic radiographs (OPGs) and CBCT scans made from January 2015 till December 2025 were checked against the set criteria. Ultimately, the dataset covered 824 implants out of which 428 were healthy and 396 were peri-implant diseased, as shown in Fig. 1a.

The index test was a CNN based on the DenseNet121 model which was programmed in Keras with a TensorFlow backend. This model was picked because of its effective use of features and stable gradient flow. The model started out with Imagenet weights pretrained. Transfer learning was done by freezing the early layers to preserve the general image features and then the later layers were retrained for classification. Gradual fine-tuning helped to further enhance peri-implant feature detection on radiographs.

The reference standard was the independent evaluation of oral health professionals trained for the task and overseen by a senior oral radiologist. Implants were divided into healthy, peri-implantitis, retrograde peri-implantitis, or prosthetically induced bone loss. Differences were settled by discussion to establish the final truth dataset.

To avoid bias, the annotators did not know the AI outputs, and the model was trained independently without the use of demographic data (Fig. 1b). Images were labelled using V7 Darwin software which allowed polygon-based segmentation of implants and defect areas.

Diagnostics performance was assessed by accuracy sensitivity specificity precision F1-score, and ROC-AUC. Cohen's kappa was used to measure the inter-observer agreement. The Hanley and McNeil method was employed to check the differences between OPG and CBCT with $\rho < 0.05$ considered statistically significant. All the analyses were done on a Linux-based system with the help of Python, TensorFlow, and GPU acceleration (Fig. 1b).

Results. Study population: A total of 824 implants were investigated; among them 428 were healthy implants and 396 with peri-implant diseases. The assessment of all the cases was performed using both panoramic radiographs (OPGs) and CBCT scans. The CNN model was independently tested for each lesion category and imaging modality.

On panoramic radiographs (OPG), the CNN demonstrated moderate to good diagnostic performance across lesion types. For maxillary peri-implantitis (PI),



(a) (b)

Fig. 1. (a) Inclusion and exclusion criteria for the OPGs and CBCTs. (b) Workflow for image annotation process, CNN architecture, data augmentation and training protocol, validation methodology, performance evaluation and computational environment

the model achieved an AUC of 0.695 with high sensitivity and moderate specificity, indicating strong detection ability but a noticeable rate of false positives (Fig. 2a, Table 1). Mandibular PI showed the best performance among OPG categories, with an AUC of 0.755, reflecting good discriminatory power. Retrograde peri-implantitis results were more balanced, with maxillary lesions yielding an AUC of 0.635 and mandibular lesions improving slightly to 0.700. For prosthetically induced peri-implant bone loss, the model performed reasonably well, achieving AUC values of 0.725 in the maxilla and 0.710 in the mandible, indicating consistent but moderate classification capability across regions.

On CBCT images, the CNN showed comparable and, in some cases, improved performance. Maxillary peri-implantitis (PI) reached an AUC of 0.715, slightly higher than OPG due to better 3D bone visualization. Mandibular PI decreased to 0.630 with lower specificity. For retrograde peri-implantitis (RPI), CBCT improved maxillary detection (AUC 0.710 vs 0.635), while mandibular results remained similar at 0.700. Prosthetically induced bone loss showed AUCs

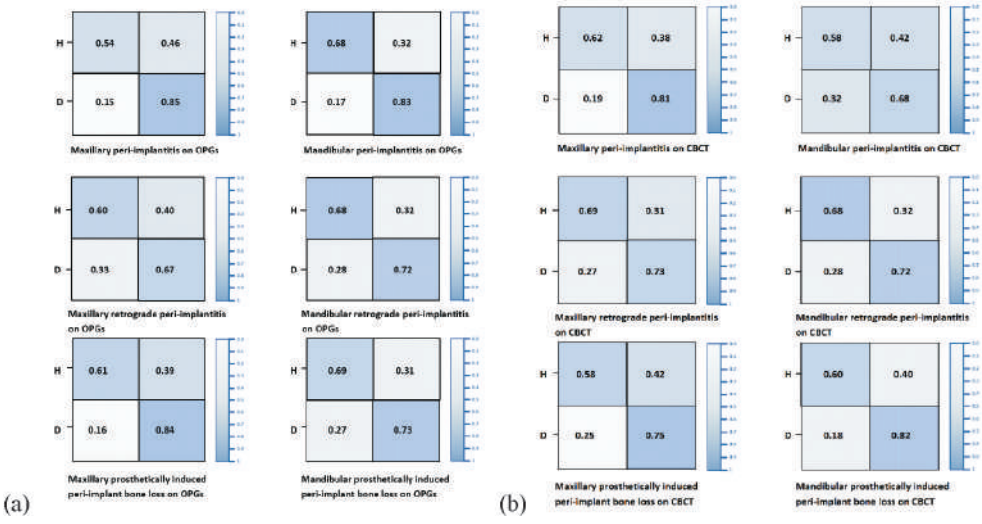

Fig. 2. Confusion matrices of CNNs show the potential to identify the healthy (H) and diseased implant associated periodontal tissues (a) observed in OPGs, (b) observed in CBCTs

of 0.665 (maxilla) and 0.710 (mandible), with overall more balanced diagnostic performance.

A comparative AUC analysis using the Hanley and McNeil method showed significant differences between OPG and CBCT depending on lesion type and location. OPG performed better for mandibular peri-implantitis (PI) than CBCT (AUC 0.755 vs. 0.630, $\rho < 0.001$), while CBCT showed superior performance for maxillary retrograde peri-implantitis (RPI) (AUC 0.710 vs. 0.635, $\rho = 0.016$) (Table 1). No significant differences were observed for maxillary PI ($\rho = 0.53$), mandibular RPI ($\rho = 1.00$), or mandibular prosthetically induced bone loss ($\rho = 1.00$), with only a borderline difference in the maxilla ($\rho = 0.051$) favouring OPG. Overall, AUC values ranged from 0.630 to 0.755, indicating moderate diagnostic performance. These findings suggest that diagnostic advantage is not modality-dependent alone but varies with lesion type and anatomical region, highlighting the need for context-specific imaging selection in AI-assisted diagnosis.

Discussion. The increasing use of artificial intelligence (AI) in medical imaging has transformed diagnostic approaches, though its role in dental implant radiology remains under active development. While AI-assisted interpretation promises efficiency, concerns persist regarding the consistency and reliability of AI-generated findings [10, 11]. This study aimed to evaluate convolutional neural network (CNN)-based models for early detection and classification of implant-related lesions using both orthopantomograms (OPG) and cone beam computed tomography (CBCT). The direct comparison within a single dataset follows current validation recommendations for AI in imaging [7].

Table 1

Diagnostic performance of AI-powered convolutional neural networks for early detection of dental implant-related lesions, presented as accuracy, precision, recall, F1-score, and area under the ROC curve (AUC)

Type of lesion	Accuracy	Precision	Recall	F1 Score	AUC Values
OPGs					
Maxillary peri-implantitis	0.689	0.631	0.850	0.724	0.695
Mandibular peri-implantitis	0.752	0.706	0.830	0.762	0.755
Maxillary retrograde peri-implantitis	0.633	0.608	0.670	0.638	0.635
Mandibular retrograde peri-implantitis	0.699	0.675	0.720	0.697	0.700
Maxillary prosthetically induced peri-implant bone loss	0.721	0.666	0.840	0.743	0.725
Mandibular prosthetically induced peri-implant bone loss	0.709	0.685	0.730	0.707	0.710
CBCTs					
Maxillary peri-implantitis	0.711	0.664	0.810	0.729	0.715
Mandibular peri-implantitis	0.628	0.600	0.680	0.637	0.630
Maxillary retrograde peri-implantitis	0.709	0.685	0.730	0.707	0.710
Mandibular retrograde peri-implantitis	0.699	0.676	0.720	0.697	0.700
Maxillary prosthetically induced peri-implant bone loss	0.662	0.623	0.750	0.681	0.665
Mandibular prosthetically induced peri-implant bone loss	0.706	0.655	0.820	0.728	0.710

The results showed that CNN models achieved good diagnostic accuracy overall, with CBCT outperforming OPG in most lesion categories. This can be attributed to CBCT's superior spatial resolution and three-dimensional visualization, which enhanced sensitivity and specificity, particularly for early peri-implant bone defects and retrograde peri-implantitis. These findings support earlier evidence that AI performance improves with higher-quality imaging data [7].

Although previous studies have reported strong CNN performance on 2D radiographs [3, 12], this study found that accuracy varied across lesion types. For example, prosthetically induced peri-implant bone loss showed similar results with both modalities, whereas early peri-implantitis detection clearly benefited from CBCT. This highlights the importance of interpreting AI outcomes in relation to lesion characteristics rather than generalizing performance [7].

Unlike multi-centre studies reporting accuracy above 80% [3], this work used a standardized institutional dataset, improving internal consistency but limiting generalizability. Imaging quality and preprocessing also played a key role in model

performance [12]. While CBCT offered superior results, its higher cost and radiation exposure must be considered. Therefore, OPG remains useful for initial AI-based screening, with CBCT reserved for confirmation.

AI integration into clinical workflows requires standardized datasets and validation methods to ensure reproducibility [13]. Despite promising results, further multi-centre research is necessary to confirm broader applicability [14].

Conclusion. The current research highlights that the use of CNNs can have a significant impact on the early detection and classification of lesions associated with dental implants, particularly when three-dimensional data from CBCT scans are utilised. On the one hand, two-dimensional panoramic X-rays are a cheap and easy way to make an initial assessment of the problem; on the other hand, the use of CBCT provides better spatial resolution and offers comprehensive anatomical information, which significantly improves the accuracy of diagnosing different lesion subtypes, thereby enabling more precise and timely treatment. However, the introduction of artificial intelligence technologies into clinical practice requires extensive testing on various datasets and careful consideration of issues such as data variability and image quality.

REFERENCES

[1] Boukhris H., G. Bouslama, H. Zidani et al. (2025) Artificial intelligence in dental implant identification: a comprehensive overview, Med. Sci. Trends Innov., **7**, 40–47.

[2] Lee J.-H., Y.-T. Kim, J.-B. Lee (2024) Identification of dental implant systems from low-quality and distorted dental radiographs using AI trained on a large multicenter dataset, Sci. Rep., **14**(1), 12606.

[3] Park W., J.-K. Huh, J.-H. Lee (2023) Automated deep learning for classification of dental implant radiographs using a large multi-center dataset, Sci. Rep., **13**(1), 4862.

[4] Jang W. S., S. Kim, P. S. Yun et al. (2022) Accurate detection for dental implant and peri-implant tissue by transfer learning of Faster R-CNN: a diagnostic accuracy study, BMC Oral Health, **22**(1), 591.

[5] Ou-Yang S., S. Han, D. Sun et al. (2023) The preliminary in vitro study and application of deep learning algorithm in cone beam computed tomography image implant recognition, Sci. Rep., **13**, 18467.

[6] Sukegawa S., K. Yoshii, T. Hara et al. (2025) Optimizing dental implant identification using deep learning leveraging artificial data, Sci. Rep., **15**(1), 3724.

[7] Mugri M. H. (2025) Accuracy of artificial intelligence models in detecting peri-implant bone loss: a systematic review, Diagnostics (Basel), **15**(6), 655.

[8] Vera M., M. J. Gómez-Silva, V. Vera et al. (2023) Artificial intelligence techniques for automatic detection of peri-implant marginal bone remodeling in intraoral radiographs, J. Digit. Imaging, **36**(5), 2259–2277.

[9] Al-Asali M., A. Y. Alqutaibi, M. Al-Sarem et al. (2024) Deep learning-based approach for 3D bone segmentation and prediction of missing tooth region for dental implant planning, Sci. Rep., **14**, 13888.
[10] Tzortzakis N. G., S. Damaskos, K. Dimakopoulou et al. (2025) Periapical radiographs vs cone beam CT imaging for the evaluation of peri-implant bone defects: an ex vivo study, Med. Oral Patol. Oral Cir. Bucal, **30**(3), e322.
[11] Qamar Z., E. Alturki, H. Almutawtah et al. (2025) AI-powered CNNs analysis of mandibular first premolars radiographic morphology for sexual dimorphism in the South Western population, Int. J. Morphol., **43**(2), 365–372.
[12] Alotaibi G., M. Awawdeh, F. F. Farook et al. (2022) Artificial intelligence (AI) diagnostic tools: utilizing a convolutional neural network (CNN) to assess periodontal bone level radiographically – a retrospective study, BMC Oral Health, **22**(1), 399.
[13] Zaww K., H. Abbas, J. R. V. Sáenz et al. (2025) AI-driven innovations for dental implant treatment planning: a systematic review, J. Prosthodont. Res., **70**(2), 192–205.
[14] Jundaeng J., R. Chamchong, C. Nithikathkul (2025) Artificial intelligence-powered innovations in periodontal diagnosis: a new era in dental healthcare, Front. Med. Technol., **6**, 1469852.

Department of Oral & Maxillofacial Surgery and Diagnostic Sciences,
College of Medicine and Dentistry, Riyadh Elm University, Riyadh, Saudi Arabia
e-mails: zeeshan.qamar@ymail.com/zeeshan.qamar@ryadh.edu.sa,
naser.a.taqi2020@student.riyadh.edu.sa,
mustafa.m.amous2020@student.ryadh.edu.sa,
Khaled.k.alkhatib2020@student.ryadh.edu.sa,
hussain.a.alenezi2020@student.ryadh.edu.sa